

# Sequential Ureterocalicostomy for An Adult Patient with Bilateral Ureteropelvic Obstruction Complicated with Kidney Stones

© Ahmet Cihan

Niğde Ömer Halisdemir University Faculty of Medicine, Department of Urology, Niğde, Türkiye

## Abstract

Ureterocalicostomy is generally known as a salvage procedure performed for indications of ureteropelvic junction stricture recurrence and/or upper ureteric injury that precludes dependent ureteropelvic anastomosis. Here we report a patient with bilateral ureteropelvic junction obstruction and an intrarenal pelvis anomaly complicated with pelvic and lower calyceal kidney stones treated with bilateral sequential ureterocalicostomy with successful outcomes at the 1-year follow-up.

**Keywords:** Ureterocalicostomy, ureterocaliceal anastomosis, ureteropelvic junction obstruction

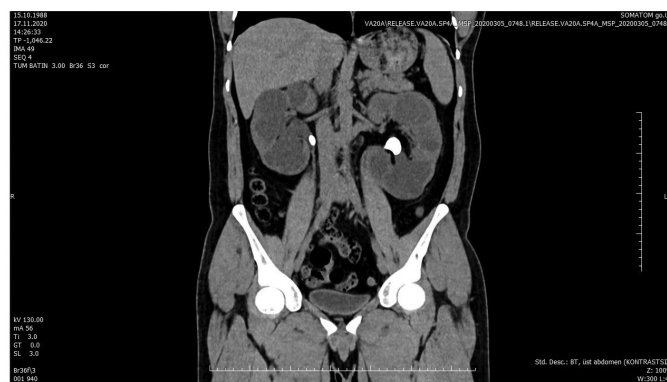
## Introduction

Open, laparoscopic, and robotically assisted laparoscopic approaches can be used for ureterocalicostomy (UC) in both pediatric and adult patients (1-5). Recent reports have revealed that UC may also be useful as a primary procedure for treatment-naïve pediatric patients with ureteropelvic junction strictures and some patients with anatomical variations, such as giant hydronephrosis and/or intrarenal pelvis with or without kidney malrotation (6-9).

## Case Presentation

A 32-year-old man was admitted to our outpatient clinic with sonographic findings of bilateral nephrolithiasis and high-grade hydronephrosis. His past medical history and physical examination did not reveal any pathological conditions. Computed tomography without contrast enhancement and serum biochemical evaluation revealed a mildly decreased glomerular filtration rate (e-GFR=88 mL/min) with bilateral nephrolithiasis, with a diameter of 13 mm at the right ureteropelvic junction (UPJ), three other stones in the lower calyces up to 6 mm in diameter in the right kidney, a stone with a diameter of 23 mm at the left renal pelvis, and a second

14 mm stone in the left lower pole calyx. The measured stone densities for the right and left kidneys were 906 and 1422 HU, respectively. Bilateral hydronephrosis (SFU grades 4 and 3, respectively) in the right and left kidneys was also reported, as shown in Figure 1. Therefore, retrograde intrarenal surgery for the right-sided stones and simultaneous endoscopic combined intrarenal surgery on the left side were offered to the patient as an initial treatment. In the first session of the surgery, despite the difficult anatomy of the right upper ureter, right flexible ureteroscopic lithotripsy with a Holmium-Yag laser was



**Figure 1.** Preoperative coronal image of computerized tomography that demonstrates bilateral giant hydronephrosis and kidney stones in the case

**Correspondence:** Ahmet Cihan MD, Niğde Ömer Halisdemir University Faculty of Medicine, Department of Urology, Niğde, Türkiye

**Phone:** +90 506 2317354 **E-mail:** ahmetcihan@ohu.edu.tr **ORCID-ID:** orcid.org/0000-0001-5586-8673

**Received:** 16.04.2023 **Accepted:** 19.06.2023

**Cite this article as:** Cihan A. Sequential Ureterocalicostomy for An Adult Patient with Bilateral Ureteropelvic Obstruction Complicated with Kidney Stones. J Urol Surg 2024;11(1):49-51.

©Copyright 2024 by the Association of Urological Surgery / Journal of Urological Surgery published by Galenos Publishing House. Licenced by Creative Commons Attribution-NonCommercial-NoDerivatives (CC BY-NC-ND) 4.0 International License.



completed, and a Double-J (DJ) stent was inserted as planned. However, surgery for the left kidney stone was unsuccessful. The intrarenal anatomy of both the pelvis and the stone, with a very long segment and dilated infundibular anatomy of the left kidney, precluded access for lithotripsy. However, a DJ stent was inserted. The postoperative course was uneventful. Within three months after the first surgical session, the patient underwent three sessions of extracorporeal shock wave lithotripsy for the left pelvic stone with the aim of fragmenting the impacted stones in the UPJ that precluded contrast passage to stone-bearing calyces, followed by one session of supine percutaneous nephrolithotomy. The bilateral DJ stents were then removed and renal scintigrams were obtained when the patient retained stones only in the lower pole calyces. Bilateral obstructive renography patterns with split functions of 34% and 66% for the right and left kidneys, respectively, were reported. Thus, the final diagnosis was congenital bilateral UPJ obstruction with an intrarenal pelvis accompanied by residual stones at the lower pole calyces (up to 5 mm on the right side and up to 18 mm on the left side). The renal cortical thickness measurements were 3 and 5 mm for the right and left kidneys, respectively.

We proceeded with planning for two additional consecutive surgical treatment sessions. In the first session, the left kidney was treated with nephropylolithotomy, accompanied by UC and DJ stent insertion via a left lumbotomy incision. We performed a 2 cm incision in the lower pole of the kidney and ureterocalyceal anastomosis with a 3.0 absorbable suture in an interrupted fashion. The operative procedure lasted four hours. Two months after the left-sided surgery, right-sided retroperitoneoscopic UC with DJ stent insertion was performed laparoscopically in the same manner. The operative time was three hours. Lower pole parenchymal resection was not required to establish appropriate ureterocalyceal anastomosis. No complications occurred in either the perioperative or postoperative periods of the surgical sessions. The DJ stents were removed cystoscopically 4 weeks after each surgery. At the 12-month follow-up visit, the patient

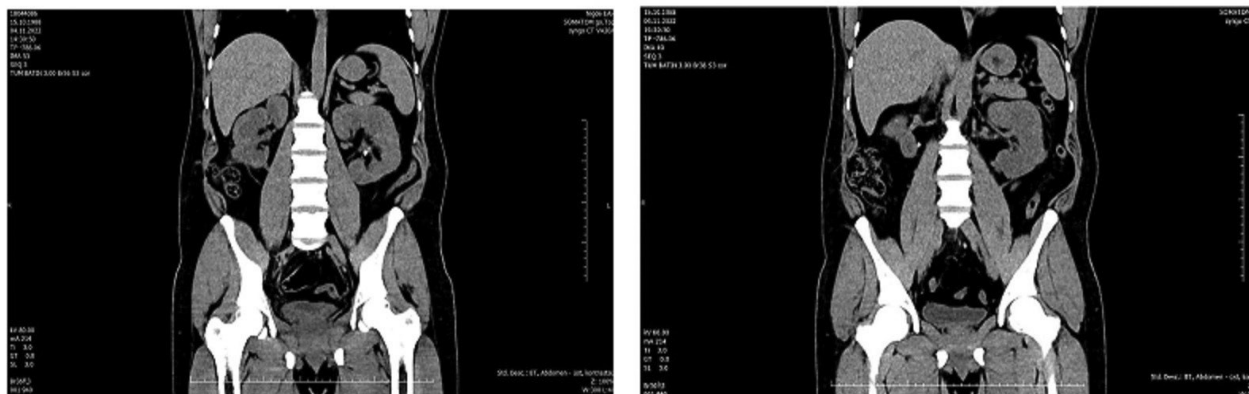
was asymptomatic, and the hydronephrosis of both kidneys was reduced (Figure 2). Residual fragments were observed only in the lower pole calyces with diameters <5 mm. The analysis of the removed stones by X-ray diffraction revealed the whewellite content. The patient's GFR had improved to 111 mL per minute.

## Discussion

To the best of our knowledge, this is the first case in the literature in which bilateral UC procedures were performed sequentially. The patient was initially diagnosed with bilateral renal pelvic and lower pole stones with giant hydronephrosis. Following the routine initial treatment sessions for both kidneys, we noticed a bizarre anatomy that precluded routine intraoperative surgical procedures. Following three endourological surgical sessions for stone fragmentation and removal from both kidneys, the final diagnoses were bilateral ureteropelvic junction obstruction with intrarenal pelvis and giant hydronephrosis. Therefore, we performed bilateral UC (open procedure on the left side and retroperitoneoscopic procedure on the right side) sequential. Subsequent workup revealed good outcomes without any complications at 12 months.

The indication for UC in the current case was bilateral giant hydronephrosis with intrarenal pelvic variation, which was concordant with previously reported findings in the literature (6-8). Recent case reports and comparative studies support this policy in patients with giant hydronephrotic kidneys and/or intrarenal pelvis with comparable results (9).

The presence of a low preoperative GFR (less than 20 mL per minute) and a thinned-out cortex (less than 5 mm) has been reported to be an independent predictor of poor surgical outcomes (2). Although the renal parenchymal thickness measurements for both kidneys were in the marginal zone in our case, preoperative GF was good, and we achieved good surgical outcomes by symptomatic and functional healing at the 12<sup>th</sup> month. In the current report, the shortness of the



**Figure 2.** Postoperative coronal image of computerized tomography obtained at one-year follow-up demonstrates resolved hydronephrosis and ureterocaliceal anastomosis of both kidneys of the case

follow-up evaluation is a limiting factor in establishing an overall conclusion.

## Conclusion

In conclusion, with appropriate indications, bilateral sequential UC for ureteropelvic junction obstruction may be performed with good surgical outcomes. Bilateral renal involvement or accompanying kidney stones may not interfere with treatment results.

## Ethics

**Informed Consent:** Informed consent was obtained for this report from the patient.

**Financial Disclosure:** The author declared that this study received no financial support.

## References

1. Nishimura Y, Moriya K, Nakamura M, Kitta T, Kanno Y, Chiba H, Kon M, Shinohara N. Laparoscopic ureterocalicostomy for ureteropelvic junction obstruction in a 10-year-old female patient: a case report. *BMC Res Notes* 2017;10:247.
2. Srivastava D, Sureka SK, Yadav P, Bansal A, Gupta S, Kapoor R, Ansari MS, Srivastava A. Ureterocalicostomy for Reconstruction of Complicated Ureteropelvic Junction Obstruction in Adults: Long-Term Outcome and Factors Predicting Failure in a Contemporary Cohort. *J Urol* 2017;198:1374-1378.
3. Ragoori D, Chiruvella M, Kondakindi PR, Bendigeri MT, Enganti B, Ghose SM. Upper Ureteric Stricture Secondary to Celiac Plexus Block Managed by Robotic Ureterocalicostomy. *J Endourol Case Reports* 2018;4:183-185.
4. Lobo S, Mushtaq I. Laparoscopic ureterocalicostomy in children: The technique and feasibility. *J Pediatr Urol* 2018;14:358-359.
5. Adamic BL, Lombardo A, Andolfi C, Hatcher D, Gundeti MS. Pediatric robotic-assisted laparoscopic ureterocalicostomy: Salient tips and technical modifications for optimal repair. *BJUI Compass* 2021;2:53-57.
6. Divjak N, Birraux J, Chehade H, Sanchez O. Hydronephrosis caused by kidney malrotation. *Urol Case Reports* 2021;36:101564.
7. Ansari MS, Danish N, Yadav P, Kaushik VN, Kakoti S, Kumar A, Banthia R, Srivastava A. Role of ureterocalicostomy in management of giant hydronephrosis in children in contemporary practice: Indications, outcomes and challenges. *J Pediatr Urol* 2021;17:657.e1-657.e7.
8. Mittal S, Aghababian A, Eftekharzadeh S, Saxena S, Janssen K, Lombardo A, Adamic B, Dinardo L, Weaver J, Fischer K, Andolfi C, Long C, Weiss D, Kirsch A, Srinivasan A, Gundeti M, Shukla AR. Robot-Assisted Laparoscopic Ureterocalicostomy in the Setting of Ureteropelvic Junction Obstruction: A Multi-Institutional Cohort. *J Urol* 2022;208:180-185.
9. Esposito C, Blanc T, Patkowski D, Lopez PJ, Masieri L, Spinoit AF, Escolino M. Laparoscopic and robot-assisted ureterocalicostomy for treatment of primary and recurrent pelvi-ureteric junction obstruction in children: a multicenter comparative study with laparoscopic and robot-assisted Anderson-Hynes pyeloplasty. *Int Urol Nephrol* 2022;54:2503-2509.