

A Rare Neoplasm of the Kidney: A Female Patient as the First Case Possibly Triggered by Pregnancy

© Kadir Şerefhan Erten¹, © Serhat Çetin¹, © Melike Urgancı², © İpek Işık Gönül², © Mustafa Özgür Tan¹

¹Gazi University Faculty of Medicine, Department of Urology, Ankara, Türkiye

²Gazi University Faculty of Medicine, Department of Pathology, Ankara, Türkiye

Abstract

Mixed epithelial and stromal tumor (MEST) is a rare, biphasic adult renal tumor composed of solid and cystic areas with spindle cell stroma and epithelium. Tumors expressing estrogen and progesterone receptors are affected by hormonal changes, often in post-menopausal women on hormone replacement therapy. Since it can be challenging to differentiate between MEST and malignant tumors, it should be considered as a differential diagnosis. To our knowledge, this is the first case postulated to be caused possibly by pregnancy-related hormonal changes. It is noteworthy that the tumor is affected by changing estrogen and progesterone hormone levels during pregnancy, thus rapidly progressing in a brief time.

Keywords: Mixed epithelial stromal tumor, early age, pregnancy

Introduction

Mixed epithelial stromal tumor (MEST) is defined as a distinct renal tumor according to the World Health Organization Classification in 2004. The tumor has cystic and solid components comprising branched glandular structures and smooth muscle-like bundles. To our knowledge, there are only one hundred reported cases in the current literature. MEST has a unique pattern that includes mesenchymal and epithelial components with characteristic estrogen and progesterone receptor-positive immunoreactive mesenchyme, mimicking ovarian stroma. Hormones are considered risk factors for these tumors, especially in women who have a history of long-term estrogen therapy post-menopause for the treatment of gynecological disorders (1-4). They are usually benign although they can rarely exhibit showing malignant behavior. The only treatment method for the tumor is surgical excision (2).

Case Presentation

A 17-year-old female patient presented to the outpatient urology clinic with a history of right flank pain for the past 7 months. She had not received any hormone therapy previously and had no significant features in her medical history except

for a recent delivery and three packs/per-year of smoking. The patient had given birth two years prior to her complaints and her kidneys were found to be normal in an ultrasound (US) conducted routinely during the postpartum period. A year after her delivery and 7 months before her admission, the patient began experiencing right flank pain. A computed tomography (CT) scan at another healthcare clinic revealed a 75 mm renal mass. A magnetic resonance imaging (MRI) done 7 months later showed a 90x70 mm high-density mass with a multicystic area in the right lower pole of the right kidney (Figure 1). The patient underwent partial nephrectomy the kidney was accessed through a right subcostal incision and the renal artery and vein were exposed and controlled. The surgical margin was then determined at the edges of the mass in the lower pole, and the mass was removed using cold ischemia for 13 minutes. Bleeding was controlled with Tissel and Surgicel, and the incision was closed with 1/0 Vicryl. A benign mesenchymal tumor was found in the frozen specimen sent intraoperatively. In our standard practice, we typically do not send frozen sections for partial nephrectomies. In this case, the patient's age was inconsistent with the development of renal cell carcinoma (RCC), prompting the need to determine a surgical approach for the tumor. Thus, frozen sections were specifically sent for this case to ensure an accurate diagnosis and appropriate treatment plan.

Correspondence: Kadir Şerefhan Erten MD, Gazi University Faculty of Medicine, Department of Urology, Ankara, Türkiye

E-mail: serefhan96@gmail.com **ORCID-ID:** orcid.org/0000-0003-1733-1765

Received: 21.03.2024 **Accepted:** 31.05.2024 **Epub:** 06.05.2025

Cite this article as: Erten KŞ, Çetin S, Urgancı M, Gönül İ, Tan MÖ. A rare neoplasm of the kidney: a female patient as the first case possibly triggered by pregnancy. J Urol Surg. [Epub Ahead of Print]

©Copyright 2025 The Author. Published by Galenos Publishing House on behalf of the Society of Urological Surgery.

This is an open access article under the Creative Commons Attribution-NonCommercial-NoDerivatives 4.0 (CC BY-NC-ND) International License.



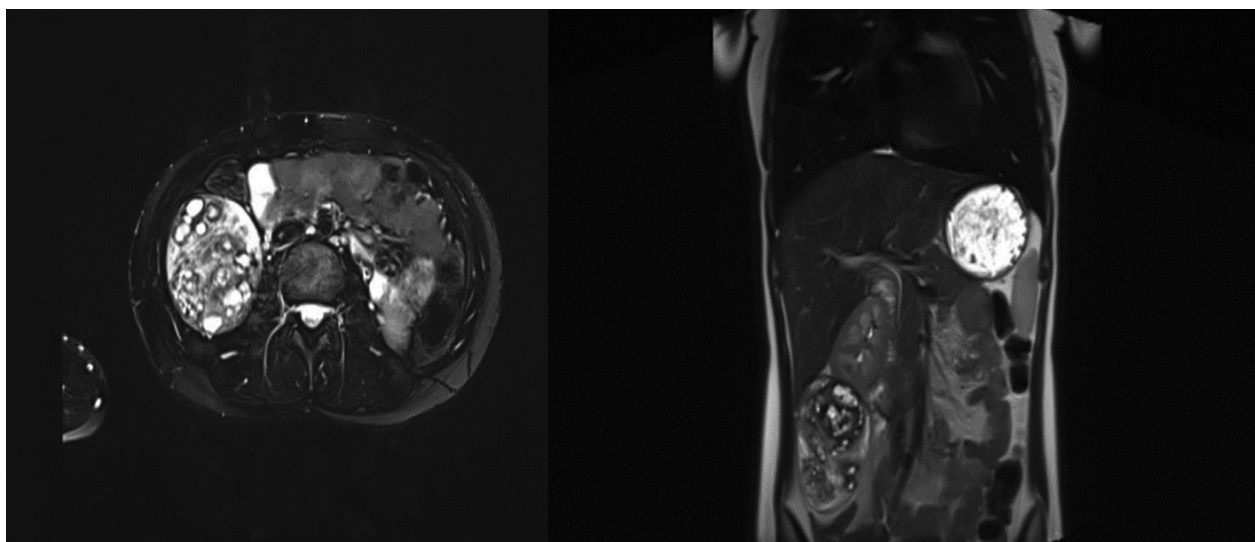


Figure 1. MRI scan image of a right renal tumor contrast retaining in transverse section and coronal section

MRI: Magnetic resonance imaging



Figure 2. Partial nephrectomy specimen showing a predominantly solid mass with microcystic areas

After surgery, the pathologic examination, revealed negative surgical margins. No invasion was observed in the renal pelvis or hilar blood vessels. There were no complications during the surgery or in the recovery period. The pathology report of a 14x8.5x5 cm mass indicated as MEST (Figure 2). The pathological evaluation of the mass lesion showed smooth muscle bundles, adipose tissue lobes, and thick-walled blood vessels in a hypocellular stroma with hyalinized and myxoid features. Multiple areas contained tubule structures and epithelial cysts of various sizes. The solid portion of the mass was composed

of moderately cellular areas of ovoid-spindle cells resembling ovarian-type stroma and rare lipocytes. There was no evidence of a blastic component nor stromal overgrowth. Cysts were lined by flattened to cuboidal, mostly bland-looking, partly hobnailed epithelial cells. Some tubules exhibited eosinophilic secretions in their tubular lumina. Immunohistochemistry demonstrated that estrogen and progesterone receptors were positive in the stromal cells while Human Melanoma Black-45 and inhibin were found to be negative.

Discussion

Mixed epithelial tumors were first described by Michal and Syrucek (5), and Adsay et al. (2) in 1998 as adult mesoblastic nephroma, cystic hamartoma of the renal pelvis, and adult nephroblastic tumors. In 2004, they were categorized as renal tumors (6). It is a rare tumor with approximately one hundred documented cases in the literature. Post-menopausal hormone therapy is the most common cause of the condition, which is typically observed in women aged 17 to and 78 years. The male to female ratio is 1:10, with rare occurrences reported in men who received hormonal therapy. Only one pediatric case has been reported. Although MEST may present with abdominal distension, flank pain, hematuria, and urinary tract infection, it is typically asymptomatic and often detected incidentally (1).

MESTs appear as well-circumscribed thin or thick multi-septate cystic components or cystic and solid areas on MRI and CT; therefore, it is difficult to distinguish them from cystic nephroma (CN) and congenital mesoblastic nephroma (7,8). On CT, the tumor can be evaluated as Bosniak type 3 and type 4 cystic lesions because they enhance contrast in the late phase

and have solid components (1). The macroscopic appearance of heterogeneous areas may include necrosis and calcification. MESTs rarely contain sinus fat tissue (9).

Our case was characterized by the development of a renal mass after pregnancy. One of the key factors that contribute to the pathogenesis of MEST is the hormonal mechanism, which is often seen in women using hormone replacement therapy during the post-menopausal period. In addition, positive staining of estrogen and progesterone receptors in immunohistochemical examination of the tumor supports this mechanism. The spindle cells found in the lesions are thought to originate from the periductal fetal mesenchyme around the epithelial structures of organs such as the kidney, pancreas, and liver. The perimenopausal period triggers the proliferation of this mesenchyme due to unopposed estrogen levels, which leads to the development of the epithelial part and the growth of tumors (10). Considering that the patient became pregnant at a young age and the tumor grew 5 cm in just two months between the MRI and surgery, it was hypothesized that the rapid proliferation of fetal mesenchymal cells was induced by hormonal changes during pregnancy.

Conclusion

The MEST family can be challenging to differentiate radiologically from other tumors, whether malignant or benign. Although exceptionally rare in children, it should be included in the differential diagnosis for Wilms tumor, CN, or pediatric RCC. In our case, the patient, who became pregnant at a young age, exhibited positive estrogen and progesterone receptors, suggesting that these hormones might have contributed to tumor stimulation. This mirrors the mechanism observed in postmenopausal patients undergoing hormone therapy. While the definitive cause of the tumor remains unclear, it is possible that hormonal fluctuations during pregnancy were influential.

Ethics

Informed Consent: Informed consent was obtained from the patient.

Authorship Contributions

Surgical and Medical Practices: S.Ç., M.Ö.T., Concept: K.Ş.E., S.Ç., M.Ö.T., Design: K.Ş.E., S.Ç., M.Ö.T., Data Collection or Processing: K.Ş.E., S.Ç., M.U., İ.I.G., M.Ö.T., Analysis or Interpretation: K.Ş.E., S.Ç., M.U., İ.I.G., M.Ö.T., Literature Search: K.Ş.E., S.Ç., M.Ö.T., Writing: K.Ş.E., S.Ç., M.Ö.T.

Conflict of Interest: No conflict of interest was declared by the authors.

Financial Disclosure: The authors declared that this study received no financial support.

References

1. Kalinowski P, Kalinowski T, Kucharz J, Kamecki H, Adamowicz B, Sikora K, Podgórska J, Demkow T. Mixed epithelial and stromal tumor of the kidney: a case report. *Oncol Lett.* 2022;25:25. [\[Crossref\]](#)
2. Adsay NV, Eble JN, Srigley JR, Jones EC, Grignon DJ. Mixed epithelial and stromal tumor of the kidney. *Am J Surg Pathol.* 2000;24:958-970. [\[Crossref\]](#)
3. Yildirim O, Alkhatalin M, Ozgen KH, Alzu'bi AY, Camurdan VB. Mixed epithelial and stromal tumor of the kidney: a case of a rare renal tumor presenting in a perimenopausal female. *Rep Pract Oncol Radiother.* 2022;27:931-932. [\[Crossref\]](#)
4. Mohanty SK, Parwani AV. Mixed epithelial and stromal tumors of the kidney: an overview. *Arch Pathol Lab Med.* 2009;133:1483-1486. [\[Crossref\]](#)
5. Michal M, Syrucek M. Benign mixed epithelial and stromal tumor of the kidney. *Pathol Res Pract.* 1998;194:445-448. [\[Crossref\]](#)
6. Ozkanli S, Zerk PE, Zemher E, Culpun M, Zenginkinet T, Aydin A. Mixed epithelial and stromal tumor of the kidney: a rare case report. *J Med Cases.* 2014;5:362-365. [\[Crossref\]](#)
7. Wood CG 3rd, Casalino DD. Mixed epithelial and stromal tumor of the kidney. *J Urol.* 2011;186:677-678. [\[Crossref\]](#)
8. Sahni VA, Morteale KJ, Glickman J, Silverman SG. Mixed epithelial and stromal tumour of the kidney: imaging features. *BJU Int.* 2010;105:932-939. [\[Crossref\]](#)
9. Durham JR, Bostwick DG, Farrow GM, Ohorodnik JM. Mesoblastic nephroma of adulthood. Report of three cases. *Am J Surg Pathol.* 1993;17:1029-1038. [\[Crossref\]](#)
10. Adsay NV, Eble JN, Srigley JR, Jones EC, Grignon DJ. Mixed epithelial and stromal tumor of the kidney. *Am J Surg Pathol.* 2000;24:958-970. [\[Crossref\]](#)