

# Urethral Diverticulum with Malignant Histology - Two Case Reports

✉ Maria Gabriela Barslev-Jensen<sup>1</sup>, ✉ Charlotte Graugaard-Jensen<sup>2</sup>, ✉ Marianne Glavind-Kristensen<sup>1</sup>, ✉ Pinar Bor<sup>1,3</sup>

<sup>1</sup>Aarhus University Hospital, Department of Obstetrics and Gynecology, Aarhus, Denmark

<sup>2</sup>Aarhus University Hospital, Department of Urology, Aarhus, Denmark

<sup>3</sup>Aarhus University Faculty of Medicine, Department of Clinical Medicine, Aarhus, Denmark

## Abstract

A female urethral diverticulum (UD) is a rare condition that poses significant diagnostic challenges due to its clinical presentation. Symptoms might be non-specific or absent, and in many patients, UD is incidentally discovered during a routine gynecological examination. The present case report describes two cases of UD, which were later diagnosed as adenocarcinoma with lymph node metastases. These cases underscore the seldom but inherent risk of malignant transformation of UD.

**Keywords:** Urethral diverticulum, adenocarcinoma, female lower urinary tract symptoms, urethral diverticulectomy, urogynecology

## Introduction

Urethral diverticulum (UD) is a rare condition affecting 1-6% of adult women, where the urethral mucosa protrudes into the surrounding tissue (1). UD commonly presents as the classic triad of dysuria, dyspareunia and post-void dribbling (2). Additional symptoms may also include recurrent urinary tract infections, vaginal discharge, or the sensation of a vaginal mass (3). However, UD can also be asymptomatic, which is why the true incidence may be underestimated. Diagnosis is based on medical history, physical examination, and diagnostic imaging (4). The condition is frequently misdiagnosed or diagnosed late due to similarity with other urinary tract or pelvic disorders (5). UD may be congenital, but it is often acquired due to previous surgeries, repeated infections or traumatic vaginal deliveries (6).

To the best of our knowledge, fewer than 130 cases of malignant transformation of the UD have been reported in the literature (7). This case report explores two additional cases of malignant transformation within a UD, contributing valuable insights to the limited knowledge on this rare condition. Written informed consent was obtained from both patients for publishing this case report and magnetic resonance images (MRIs).

## Case Presentation

### Case 1

A 78-year-old woman was referred with three months of postmenopausal bleeding, recurrent urinary tract infection, and urge incontinence. Her medical history included breast cancer treated with bilateral mastectomy and tamoxifen, rheumatoid arthritis, and lichen sclerosus. Vaginal examination revealed discharge from the urethra upon compression of the anterior vaginal wall. Ultrasound identified a 19 mm cavity associated with the urethra, consistent with a UD. Urethrocytography revealed a 5.6 cm tumor both surrounding and extending into the urethra. Aspiration from the tumor showed *E. coli*, *Bacteroides fragilis*, and *Bifidobacterium*, suggesting an abscess or a chronic infection. Transurethral biopsies were inconclusive, but high-grade adenocarcinoma originating from the urethra was suspected. MRI confirmed a malignant tumor infiltrating the urethra, UD, and anterior vaginal wall (Figure 1). Fluorodeoxyglucose positron emission tomography/computed tomography showed no lymph node metastases. Based on multidisciplinary team recommendations, the patient underwent laparoscopic cystectomy, urethrectomy, removal of internal genitalia, and ileal conduit formation. Histopathology confirmed invasive adenocarcinoma (pT3) with lymph node metastases.

**Correspondence:** Maria Gabriela Barslev Jensen MD, Aarhus University Hospital, Department of Obstetrics and Gynecology, Aarhus, Denmark

**E-mail:** Maria.gabriela@live.dk **ORCID-ID:** orcid.org/0009-0004-0679-7791

**Received:** 08.10.2024 **Accepted:** 09.01.2025 **Epub:** 16.03.2026 **Publication Date:** 01.06.2026

**Cite this article as:** Barslev-Jensen MG, Graugaard-Jensen C, Glavind-Kristensen M, Bor P. Urethral diverticulum with malignant histology - two case reports. J Urol Surg. 2026;13(2):138-140.

©Copyright 2026 The Author(s). Published by Galenos Publishing House on behalf of the Society of Urological Surgery.

This is an open access article under the Creative Commons Attribution-NonCommercial-NoDerivatives 4.0 (CC BY-NC-ND) International License.



At the eight-month follow-up, hydronephrosis, hydroureter and enlarged lymph nodes were identified with a biopsy confirming recurrent adenocarcinoma. Immunotherapy was not an option due to ongoing methotrexate treatment. The patient was referred to palliative care and ultimately died due to the progression of her disease.

## Case 2

A 46-year-old woman with no previous surgery presented with uterine prolapse. She had two vaginal deliveries. Physical examination revealed swelling near the urethra. Transvaginal ultrasound and MRI confirmed a 3.5 cm UD. As the patient was asymptomatic, no immediate intervention was performed. Two years later she returned with pain from the urethra. MRI showed no change in the size of the UD. A diverticulectomy was offered, but the patient declined the procedure. Four years later, she developed macroscopic hematuria, lower abdominal pain, urge incontinence and urethral discharge. Computed tomography imaging showed two small cysts in the left kidney and unchanged size of the UD. The hematuria was attributed to an infection in the UD. Three months later, the patient returned with vaginal bleeding and an MRI confirmed solid tumor growth within the UD (Figure 2). The patient underwent a successful transvaginal diverticulectomy. Histopathology confirmed clear cell adenocarcinoma (pT2), a very rare malignancy, with metastasis to the inguinal lymph nodes. The patient underwent radical cystectomy, removal of internal genitalia, inguinal lymph node dissection, and ileal conduit formation. Four months later, the patient developed a vaginal enterocele, which

was successfully treated with Permacol mesh. At the 36-month follow-up, ureteral dilation was performed due to stenosis, but there was no evidence of recurrence.

## Discussion

Urethral adenocarcinoma in UD is exceptionally rare and accounts for less than 0.02% of all cancer diagnoses in women (8). While adenocarcinoma is the most common histological subtype, squamous cell carcinoma and transitional cell carcinoma have also been reported (9). Prognosis depends on local tumor extent and lymph node involvement, but there is still no consensus on which histological subtypes are associated with the poorest prognosis (9).

Notably, the classic symptoms of UD dysuria, dyspareunia and post-void dribbling were absent in our cases. Instead, the patients presented with non-specific symptoms such as postmenopausal bleeding and vaginal mass, leading to initial diagnoses including abscess, vaginal cyst, or infection. A heterogenic structure, solid elements, or increasing growth of a UD may indicate a higher risk of malignancy (10). The diagnostic challenges associated with UD emphasize the need for detailed patient history, physical examination, and MRI should be considered for a comprehensive evaluation of the UD (5).

Numerous treatments of UD have been proposed in the literature and vary from no intervention to surgical intervention. The largest case series to date on UD in women included 228 cases, and 172 underwent transvaginal diverticulectomy (1).

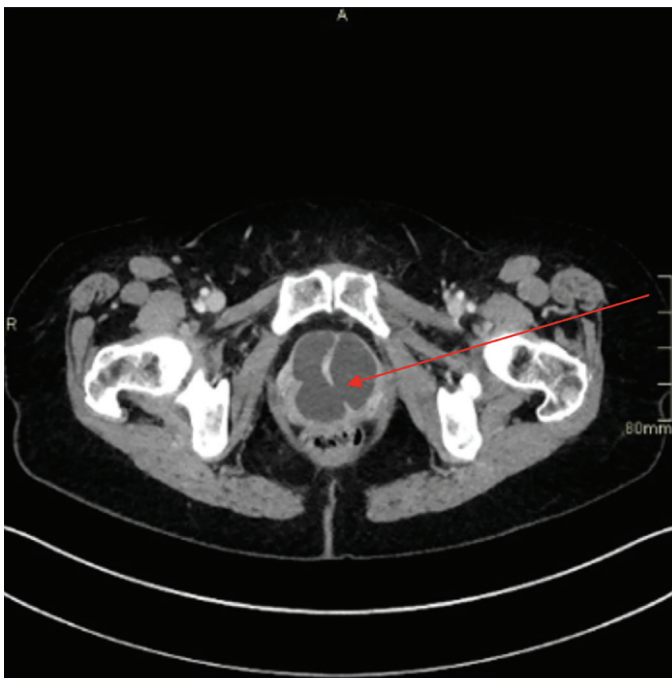


Figure 1. Axial cut of the urethral diverticula

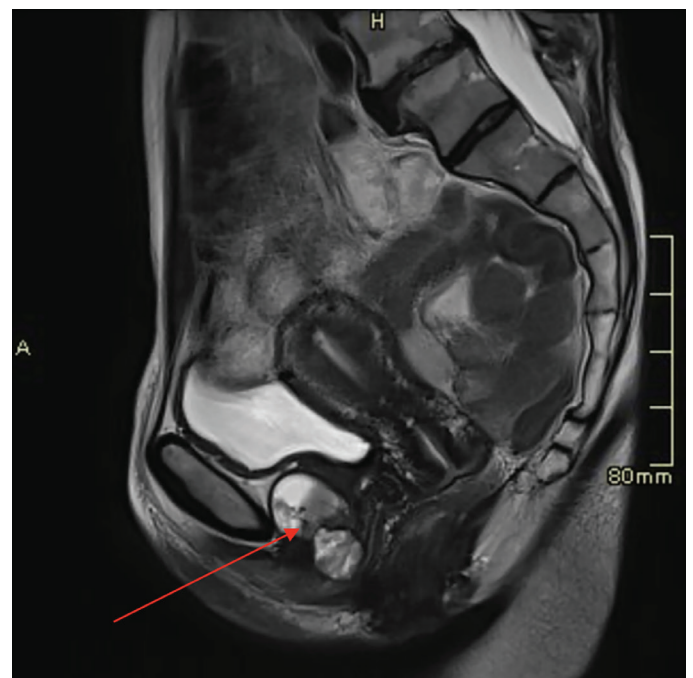

Figure 2. Sagittal plane of the urethral diverticula

Transvaginal diverticulectomy is the most described treatment modality in the literature and is performed in most cases with a cure rate up to 86% (11,12).

Complications of transvaginal diverticulectomy include infection, fistula formation, urethral stenosis, and de novo stress urinary incontinence (13). Recurrence rates of UD following surgery range from 1.4 to 23.4% and may arise due to inadequate removal of the UD sac or a subsequent infection (1,4,13). Successful surgical removal of the UD requires complete removal of the UD sac, urethral closure in a watertight manner, and multi-layered closure using absorbable sutures. Pathological evaluation of the excised tissue is essential to rule out malignancy. In cases of confirmed malignancy, more extensive surgical intervention is warranted, such as cystectomy combined with urethrectomy and ileal conduit formation, as demonstrated by our two cases. However, the rarity and histological variability of malignant UD make it challenging to develop standardized management guidelines, which are currently lacking.

## Conclusion

These cases highlight the importance of considering UD in the differential diagnosis of women presenting with atypical urinary tract or pelvic disorders. Moreover, the potential risk of malignant transformation, although rare, emphasizes the need for comprehensive evaluation and early intervention. Advancing our understanding of this rare condition will be pivotal in refining management guidelines and improving patient outcomes.

## Ethics

**Informed Consent:** Written informed consent was obtained from both patients for publishing this case report and magnetic resonance images.

## Footnotes

### Authorship Contributions

Surgical and Medical Practices: M.G.B-J., C.G-J., M.G-K., P.B., Concept: M.G.B-J., C.G-J., M.G-K., P.B., Design: M.G.B-J., C.G-J., M.G-K., P.B., Data Collection or Processing: M.G.B-J., C.G-J., M.G-K., P.B., Literature Search: M.G.B-J., C.G-J., M.G-K., P.B., Writing: M.G.B-J., C.G-J., M.G-K., P.B.

**Conflict of Interest:** No conflict of interest was declared by the authors.

**Financial Disclosure:** The authors declared that this study received no financial support.

## References

1. Vaidya RV, Olson K, Wolter C, Khan A. Characterization of urethral diverticula in women. *Female Pelvic Med Reconstr Surg.* 2022;28:54-56. [\[Crossref\]](#)
2. Baradaran N, Chiles LR, Freilich DA, Rames RA, Cox L, Rovner ES. Female urethral diverticula in the contemporary era: is the classic triad of the "3Ds" still relevant? *Urology.* 2016;94:53-56. [\[Crossref\]](#)
3. Barakat B, Franke K, Hijazi S, Wolff I, Hadaschik B, Rehme C. Correlation between symptoms and imaging findings including pelvic floor ultrasound to improve the symptom-based diagnosis of female urethral diverticulum (CHECK-UD study). *Int Urogynecol J.* 2022;33:2267-2274. [\[Crossref\]](#)
4. El-Nashar SA, Singh R, Bacon MM, Kim-Fine S, Occhino JA, Gebhart JB, Klingele CJ. Female urethral diverticulum: presentation, diagnosis, and predictors of outcomes after surgery. *Female Pelvic Med Reconstr Surg.* 2016;22:447-452. [\[Crossref\]](#)
5. Greiman AK, Rolef J, Rovner ES. Urethral diverticulum: a systematic review. *Arab J Urol.* 2019;17:49-57. [\[Crossref\]](#)
6. Agrawal N, Tripathi S, Kathuria P, Shekhar S, Bhirud DP, Yadav T, Singh M. Large urethral diverticular calculus clinically mimicking a metastatic deposit in a case of ovarian mass. *J Obstet Gynaecol India.* 2023;73(Suppl 2):304-307. [\[Crossref\]](#)
7. O'Connor E, Iatropoulou D, Hashimoto S, Takahashi S, Ho DH, Greenwell T. Urethral diverticulum carcinoma in females—a case series and review of the English and Japanese literature. *Transl Androl Urol.* 2018;7:703-729. [\[Crossref\]](#)
8. Torrez MM, Alba FM, Zhou J. A PAX-8-positive female urethral adenocarcinoma, intestinal-type: a case report with diagnostic challenges and a review of the literature. *Case Rep Pathol.* 2023;2023:8323821. [\[Crossref\]](#)
9. Oluyadi F, Ramachandran P, Gotlieb V. A rare case of advanced urethral diverticular adenocarcinoma and a review of treatment modalities. *J Investig Med High Impact Case Rep.* 2019;7:2324709619828408. [\[Crossref\]](#)
10. Zuo SW, Napoe GS. Evaluation and management of urethral and periurethral masses in women. *Curr Opin Obstet Gynecol.* 2023;35:517-524. [\[Crossref\]](#)
11. Bodner-Adler B, Halpern K, Hanzal E. Surgical management of urethral diverticula in women: a systematic review. *Int Urogynecol J.* 2016;27:993-1001. [\[Crossref\]](#)
12. Kim HW, Lee JZ, Shin DG. Pathophysiology and management of long-term complications after transvaginal urethral diverticulectomy. *Int Neurourol J.* 2021;25:202-209. [\[Crossref\]](#)
13. Malde S, Sihra N, Naaseri S, Spilotros M, Solomon E, Pakzad M, Hamid R, Ockrim JL, Greenwell TJ. Urethral diverticulectomy with Martius labial fat pad interposition improves symptom resolution and reduces recurrence. *BJU Int.* 2017;119:158-163. [\[Crossref\]](#)