

Granulomatous Cystitis in an Adult Female: A Case Report

✉ Mitchell J. Finkelstein¹, ✉ Kim Hookim², ✉ Marc Zeffren³

¹Cooper Medical School of Rowan University, New Jersey, USA

²Cooper University Hospital, Clinic of Pathology, New Jersey, USA

³Cooper University Hospital, Clinic of Urological Surgery, New Jersey, USA

Abstract

Granulomatous cystitis of the bladder is a rare urological pathology resulting from infection, Bacillus Calmette-Guerin treatment for bladder cancer, granulomatous disease, or idiopathic origins. We report a 63-year-old female with dysuria and abdominal pain. Computed tomography imaging revealed a thickening of the bladder wall, which raises concerns for malignancy. A transurethral resection of bladder tumor procedure was performed, and a biopsy revealed chronic granulomatous cystitis that was negative for malignancy. The patient experienced no complications post-operatively and was on continued oxybutynin and tamsulosin treatment. We discuss the etiologies of granulomatous cystitis and attempt to provide theories for this patient's uncommon disease.

Keywords: Functional urology, general urology, pathology, urooncology

Introduction

Granulomatous cystitis is a rare type of chronic inflammation in the bladder associated with *Mycobacterium tuberculosis* infection, *Schistosoma haematobium* infection, Bacillus Calmette-Guerin (BCG) intravesical instillation chemotherapy for the treatment of bladder cancer, and chronic granulomatous disease (1-5). Though most bladder lesions represent malignancy, benign conditions such as granulomatous cystitis must be considered in the differential diagnosis. In this report, we describe a 63-year-old woman presenting with dysuria, urinary urgency, and left-sided abdominal pain. Imaging revealed a diffuse, infiltrative-appearing bladder wall. A biopsy of the specimen revealed acute-on-chronic granulomatous inflammation consistent with granulomatous cystitis. There was no evidence of malignancy.

Case Presentation

A 63-year-old woman presented to the outpatient clinic with lower left abdominal pain, dysuria, and urinary urgency. Her past medical history includes previous breast cancer under remission, spinal stenosis, obesity, type II diabetes mellitus,

hysteroscopy, dilation, and curettage for polyp removal, and recurrent nephrolithiasis. Urinalysis revealed cloudy urine with microscopic hematuria, glucosuria, proteinuria, and pyuria. Urine culture was negative for the growth of any organism. The patient was prescribed oxybutynin for her urinary urgency, and a computed tomography (CT) of the abdomen and pelvis with and without contrast was obtained due to her chronic abdominal pain, which revealed multiple non-obstructing stones within the left renal pelvis and evidence of splenic granulomatous disease. CT urogram identified a left proximal 2 mm ureteral stone and infiltrative multifocal thickening of the bladder wall, suggestive of malignancy (Figure 1). A review of a previous CT of the chest revealed a calcified granuloma in the right middle lobe of the lung.

A transurethral resection of bladder tumor (TURBT) was performed two weeks following the appointment. The patient was placed under general endotracheal anesthesia, and the operation began by intubating the urethral meatus with a 22-French Olympus cystoscope with a 30-degree lens and a digital camera. Diffuse, bullous edematous changes to the bladder trigone and a pedunculated lesion on the left lateral wall towards the anterior wall was noted, which was consistent with findings on imaging.

Correspondence: Marc Zeffren MD, Cooper University Hospital, Clinic of Urological Surgery, New Jersey, USA

E-mail: zeffren-marc@CooperHealth.edu **ORCID-ID:** orcid.org/0000-0003-2888-8470

Received: 26.11.2024 **Accepted:** 04.03.2025 **Epub:** 16.03.2026 **Publication Date:** 01.06.2026

Cite this article as: Finkelstein MJ, Hookim K, Zeffren M. Granulomatous cystitis in an adult female: a case report. J Urol Surg. 2026;13(2):141-143.



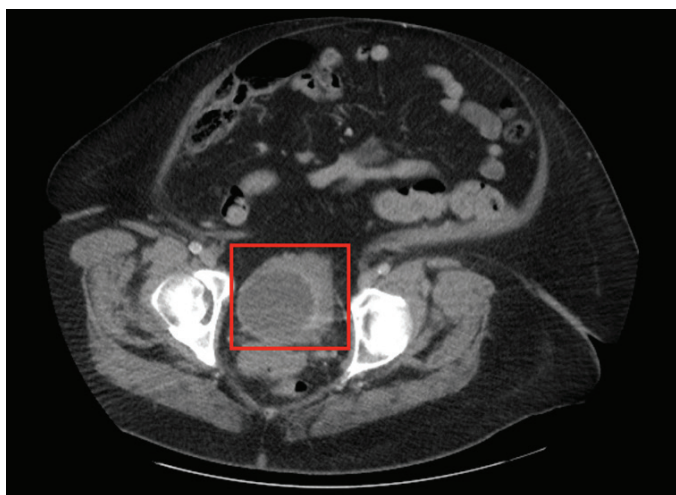


Figure 1. CT abdomen and pelvis imaging revealing granulomatous cystitis. Persistent soft tissue thickening and infiltration of the bladder anteriorly and along the left lateral wall with a mass-like component of this thickening measuring 3.8x2.6 cm along the anterior bladder floor

CT: Computed tomography

Complete resection of the bladder tumor to the muscular layer was achieved without complication. An end-loop electrode gyrus electrocautery set was used to accomplish hemostasis. A left-sided 4.7 French x 24 cm Double-J ureteral stent was placed due to the presence of left-sided collecting system dilatation, and proximal left ureteral stone. The bladder was then intubated with a 22-French Foley catheter, which drained clear urine into a drainage bag. The patient was subsequently awakened by the anesthesia team without any complications.

Biopsy revealed acute on chronic granulomatous cystitis with ulceration and granulation tissue; marked acute and chronic inflammation; and focal granulomata (Figure 2). The muscularis propria was present and negative for malignancy. Patient consent was obtained.

Discussion

Granulomatous cystitis is a rare inflammatory condition resulting from a variety of causes, including Mycobacteria or Schistosomal infections, chronic granulomatous disease, sarcoidosis, and surgical complications (1-6). The use of intravesical BCG instillation to treat intermediate or high-risk urothelial carcinoma is another common cause of granulomatous cystitis, with about 60% to 80% of patients experiencing this complication from the treatment (6,7). Due to the various causes of this condition and possible confusion with a neoplasm, it is necessary to complete a thorough patient history and to rule out infectious causes.

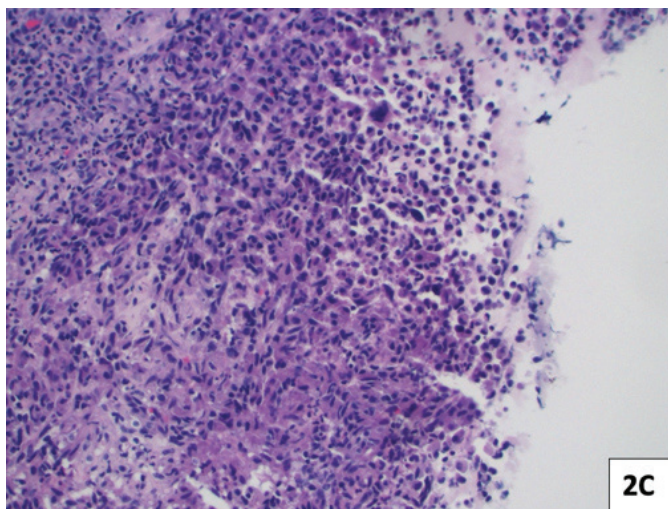
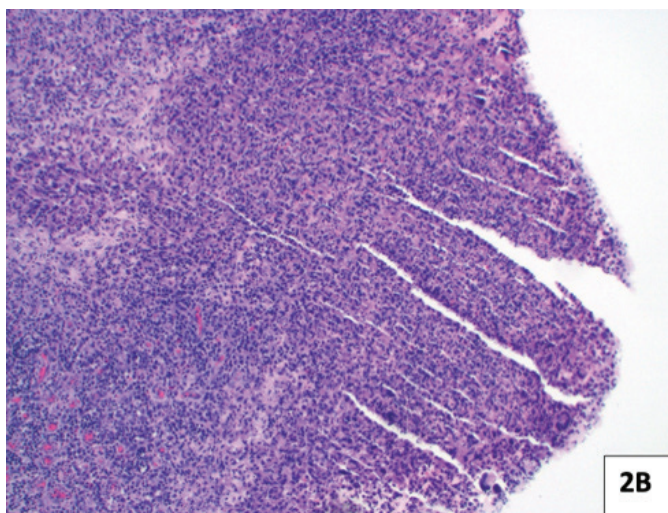
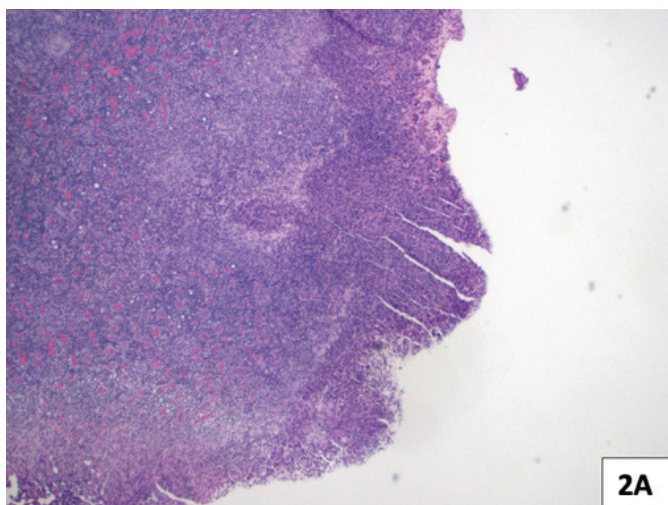


Figure 2. Histological appearance of granulomatous cystitis. Acute on chronic granulomatous cystitis with ulceration, granulation tissue with marked acute and chronic inflammation and focal granulomata; muscularis propria was present and negative for malignancy (A. H&E, 4x; B. H&E 10x, C. H&E, 20x)

H&E: Hematoxylin and eosin

The incidental CT findings of a granuloma in the right middle lobe of the lung and evidence of granulomatous disease in the spleen hint at the possible etiology of granulomatous cystitis in this patient. Genitourinary tuberculosis, which occurs in about 40% of patients following extrapulmonary tuberculosis infection, is a common complication with a latency period of up to 20 years (1). However, smear microscopy with a Ziehl-Neelsen stain and *Mycobacterium* culture was never completed, leaving this possibility open to speculation (1). Another possible cause of granulomatous cystitis in this patient could have been trauma-related, as the patient underwent hysteroscopy and dilation and curettage for polyp removal approximately a year prior to her urological symptoms. A multicenter study consisting of 21,676 hysteroscopies, in Germany, revealed an overall complication rate of 0.22%, with 0.02% of complications related to bladder or bowel injury caused by uterine perforation (8,9). Another cause of granulomatous cystitis is intravesical BCG therapy for superficial carcinoma of the bladder. Although not seen in our patient, it is important to take a proper medical history to rule this out as a possible cause of granulomatous cystitis. It is suggested that the internalization of BCG by bladder cancer cells induces an anti-tumor effect through direct cytotoxic mechanisms, with CD4⁺ Th1 cells primarily mediating this reaction (10-12).

Treatment of granulomatous cystitis can involve both pharmacological and surgical management. In the case of the former, corticosteroid and antibiotic treatment improved the bladder-related symptoms of a child with a history of chronic granulomatous disease (13). Radical cystectomy was an effective surgical option for a patient diagnosed with granulomatous cystitis secondary to an intravesical BCG treatment for urothelial carcinoma (14). In the case of our patient, a TURBT was performed due to the concern for malignancy.

Conclusion

In conclusion, we present a 63-year-old woman with abdominal pain, dysuria, and urinary urgency who was found to have an infiltrative thickening of the anterior, left, and posterior bladder walls. The patient subsequently underwent TURBT, which revealed chronic granulomatous cystitis with ulceration and granulation tissue, marked by marked acute and chronic inflammation and focal granulomata. Due to its rare incidence, further studies will be needed to evaluate effective treatment options. A thorough review of a patient's medical history is also necessary to rule out infectious or traumatic etiology.

Ethics

Informed Consent: Patient consent was obtained.

Authorship Contributions

Surgical and Medical Practices: K.H., M.Z., Concept: M.J.F., M.Z., Design: M.J.F., M.Z., Data Collection or Processing: M.J.F.,

Analysis or Interpretation: M.J.F., K.H., M.Z., Literature Search: M.J.F., Writing: M.J.F., K.H., M.Z.

Conflict of Interest: No conflict of interest was declared by the authors.

Financial Disclosure: The authors declared that this study received no financial support.

References

1. Roddy K, Tobin EH, Leslie SW, Rathish B. Genitourinary tuberculosis. [Updated 2024 Aug 16]. In: StatPearls [Internet]. Treasure Island (FL): StatPearls Publishing; 2026 Jan-. [Crossref]
2. IARC Working Group on the Evaluation of Carcinogenic Risks to Humans. Schistosomes, Liver Flukes and Helicobacter pylori. Lyon (FR): International Agency for Research on Cancer; 1994. (IARC monographs on the evaluation of carcinogenic risks to humans). [Crossref]
3. Branco EA, Duro R, Brito T, Sarmento A. Granulomatous hepatitis following intra-vesical instillation of bacillus Calmette-Guérin for treatment of bladder cancer. *Infect Dis Rep.* 2021;13:611-618. [Crossref]
4. Walther MM, Malech H, Berman A, Choyke P, Venzon DJ, Linehan WM, Gallin JI. The urological manifestations of chronic granulomatous disease. *J Urol.* 1992;147:1314-1318. [Crossref]
5. Al-Hussain T, Roychowdhury M. Granulomatous cystitis. *PathologyOutlines.com* [Internet]. 2011 Apr 1 [updated 2026 May 11; cited 2026 May 18]. [Crossref]
6. Masuoka S, Miyazaki O, Imai A, Okamoto R, Tsutsumi Y, Miyasaka M, Hasegawa Y, Yoshioka T, Nosaka S. "Another inchworm sign" on dynamic contrast-enhanced magnetic resonance imaging in pediatric patients with cystitis cystica and glandularis: radiologic-pathologic correlation. *Radiol Case Rep.* 2022;18:840-843. [Crossref]
7. O'Donnell MA. Practical applications of intravesical chemotherapy and immunotherapy in high-risk patients with superficial bladder cancer. *Urol Clin North Am.* 2005;32:121-131. [Crossref]
8. Serranito A. Operative hysteroscopy complications. *IntechOpen.* 2023. [Crossref]
9. Aydeniz B, Gruber IV, Schauf B, Kurek R, Meyer A, Wallwiener D. A multicenter survey of complications associated with 21,676 operative hysteroscopies. *Eur J Obstet Gynecol Reprod Biol.* 2002;104:160-164. [Crossref]
10. Redelman-Sidi G, Glickman MS, Bochner BH. The mechanism of action of BCG therapy for bladder cancer--a current perspective. *Nat Rev Urol.* 2014;11:153-162. [Crossref]
11. Yao Y, Ji JJ, Wang HY, Sun LJ, Zhang GM. Granulomatous prostatitis after bacille Calmette-Guérin instillation resembles prostate carcinoma: a case report and review of the literature. *World J Clin Cases.* 2023;11:2051-2059. [Crossref]
12. Ponticciello A, Perna F, Maione S, Stradolini M, Testa G, Terrazzano G, Ruggiero G, Malerba M, Sanduzzi A. Analysis of local T lymphocyte subsets upon stimulation with intravesical BCG: a model to study tuberculosis immunity. *Respir Med.* 2004;98:509-514. [Crossref]
13. Chin TW, Stiehm ER, Falloon J, Gallin JI. Corticosteroids in treatment of obstructive lesions of chronic granulomatous disease. *J Pediatr.* 1987;111:349-352. [Crossref]
14. Medina-González M, Panach-Navarrete J, Mata-Cano D, Martínez Jabaloyas JM. Microbladder due to granulomatous cystitis secondary to BCG treatment. *Arch Esp Urol.* 2022;75:729-730. [Crossref]